

# Memory and the Brain: What's Right and What's Left?

## Minireview

Russell A. Poldrack and John D. E. Gabrieli  
Department of Psychology  
Stanford University  
Stanford, California 94305-2130

Over the last 100 years, knowledge about how cognitive functions are implemented in the brain has come almost exclusively from the study of patients with brain damage. The famous case of Phineas Gage, whose personality was radically altered following a traumatic lesion to the orbitofrontal cortex, provided early evidence about the neural organization of personality and motivation. The landmark studies by Broca and Wernicke of aphasic patients with cortical lesions implicated frontal and temporo-parietal regions in language, providing a framework that remains influential to this day. Studies of these and other such patients are the foundation for most of what is presently known about the neural architecture of cognition.

Current views about the neural bases of long-term memory initially emerged from the study of a single person, H. M., who underwent bilateral excision of his medial temporal lobes (MTL: including hippocampus, amygdala, and perirhinal and entorhinal cortices, see Figure 1) in 1953 to control pharmacologically intractable epilepsy (Scoville and Milner, 1957). Following this surgery, H. M. suffered from severe anterograde amnesia (inability to remember new events) that remains to this day. The amnesia was specific to long-term memory in that he retained short-term memory for events in the past few seconds, as well as intact perceptual and cognitive capacities. The amnesia was also global: it applied to verbal and nonverbal materials, to all modalities, and to such major events as elections, wars, and the deaths of his parents.

Studies of H. M.'s memory abilities, and subsequent studies of other amnesic patients, have firmly established the critical and necessary role of the MTL in the establishment of new memories (Cohen and Eichenbaum, 1993; Poldrack and Gabrieli, 1997). Examination of patients with unilateral lesions to the MTL has demonstrated material-specificity of these memory impairments, with left hemisphere lesions impairing verbal memory and right hemisphere lesions impairing nonverbal memory for materials such as faces or meaningless patterns (Milner, 1970). The results of MTL lesion studies in humans have been impressively supported and extended by lesion studies in animals. Lesions to the hippocampus and overlying cortices result in severe memory deficits in animals, and recent studies have provided increasing specificity about the anatomical localization of memory processes in various MTL structures (Squire, 1992).

Lesion studies in humans have also associated the prefrontal cortex with memory processing. The memory deficits that follow prefrontal lesions are much less dramatic than those that follow MTL damage. Patients with prefrontal lesions are particularly impaired on complex tests such as memory for the temporal order in which information was presented, or recollection of the source of remembered information (Shimamura, 1995). In contrast to patients with MTL lesions, however, frontal patients retain good memory for the information itself. The exact nature of the memory deficits resulting from prefrontal lesions depends upon which hemisphere is damaged: left prefrontal lesions differentially impair performance on complex tests of verbal memory, whereas right prefrontal lesions differentially impair performance on complex tests of nonverbal memory (Milner, 1982).

Although lesion studies remain an essential tool for cognitive neuroscientists, they have several limitations.

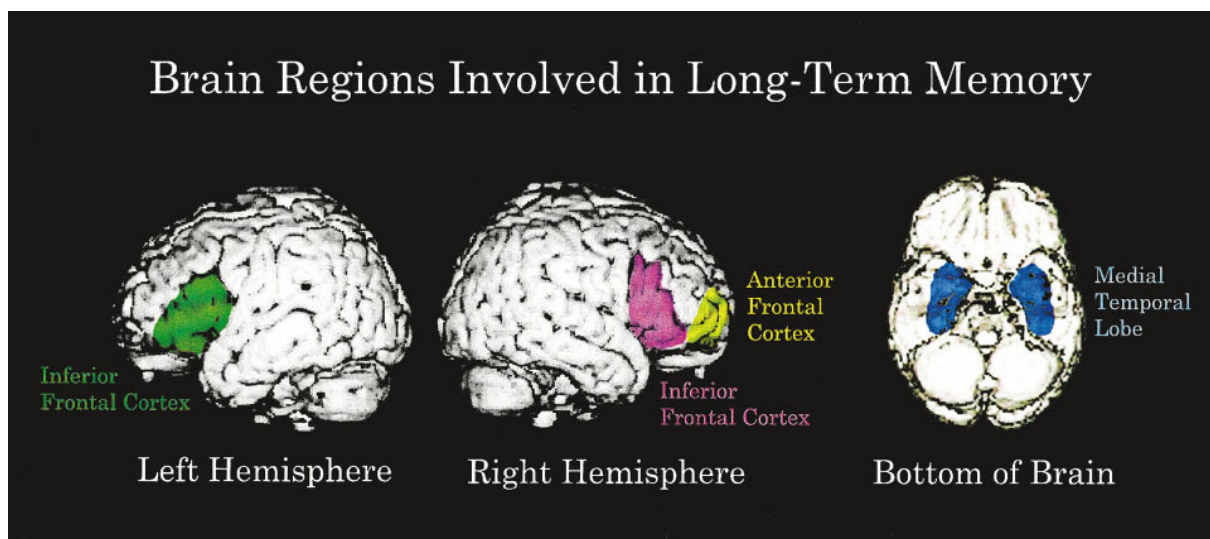


Figure 1. Depiction of Brain Regions Associated with Memory Encoding and Retrieval  
Lateral views depict left and right hemisphere frontal lobe regions, and bottom view depicts medial temporal lobe regions.

Lesions (which often occur due to stroke, infection, or trauma) can be large and rarely obey functional boundaries, making it difficult to ascribe functional impairments to a particular structure. Lesions to cortex often damage underlying fibers of passage, which can lead to deficits due to disconnection of other intact brain regions. Brain plasticity also confounds the interpretation of lesion data; because neural systems may become reorganized following injury (e.g., Buckner et al., 1996), the neural architecture of cognitive processing in a lesioned patient does not simply reflect the subtraction of the lesioned area from the normal system. Rather, behavior reflects the ability of the rest of the brain to compensate for the injury.

#### **Memory: Insights from Brain Imaging**

The recent development of functional brain imaging techniques, particularly positron emission tomography (PET) and functional magnetic resonance imaging (fMRI), has provided a set of tools that complements the study of lesioned patients. PET and fMRI image neural activity indirectly by measuring regional cerebral blood flow (PET) or blood oxygenation (fMRI), both of which increase due to local synaptic activity (Raichle, 1994). These techniques offer the ability to examine the neural processes of normal subjects *in vivo*, and thus provide a more direct view of the normal brain function than can lesion studies. fMRI offers the particularly exciting ability to image brain function with relatively fine temporal (1–3 s) and spatial (~2 mm) resolution, and to closely relate anatomy and function because anatomical and functional images can be acquired during the same scanning session.

The study of memory processes using functional imaging has provided an interesting counterpoint to the results from lesion studies. A large set of functional imaging studies has demonstrated that multiple regions in the prefrontal cortex (see Figure 1) are activated during memory encoding (recording events into memory) and memory retrieval (recovering events from memory). However, the hemispheric lateralization of prefrontal cortex suggested by these imaging studies has seemed to differ from that suggested by lesion studies. Whereas lesion data suggest that the left prefrontal cortex is important for verbal memory and right prefrontal cortex for nonverbal memory, imaging studies have implicated the left prefrontal cortex in memory encoding and the right prefrontal cortex in memory retrieval. Tulving and his colleagues (Tulving et al., 1994) proposed the “Hemispheric Encoding/Retrieval Asymmetry” (HERA) framework to describe this set of findings, and this model has received support from a number of studies according to a recent meta-analysis (Nyberg et al., 1996). The HERA model posits that lateralization of memory processing depends exclusively upon the encoding/retrieval distinction and does not depend upon whether the material being learned or remembered is verbal or nonverbal. However, most of the studies that support the HERA model have examined memory for verbal material, and none has directly compared encoding and retrieval for both verbal and nonverbal materials.

#### **Convergence across Methods**

A recent study by Kelley et al. (1998) provides an important rapprochement of the neuropsychological and imaging approaches to hemispheric specialization in memory encoding. This study used fMRI to examine brain

activation during encoding into memory of three types of stimuli: words (which obligatorily engage verbal processing), line drawings of common objects (which engage both verbal processing and form-based visual processing), and unfamiliar faces (which are difficult to label verbally and rely upon processing of visual form). Images obtained during the encoding of each of these stimuli were compared to a baseline task in which subjects fixated visually on a crosshair. Brain regions demonstrating enhanced fMRI signal (denoting increases in blood oxygenation and, by inference, increases in synaptic activity) during the memory-encoding periods compared to the fixation period included the prefrontal cortex and MTL. Notably, the lateralization of activation during encoding was determined by the nature of the stimulus materials. Consonant with the results of lesion studies, the left posterior prefrontal cortex (Brodmann's area [BA] 44/6) was most active during encoding of words, the right posterior prefrontal cortex (BA 44/6) was most active during encoding of faces, and both hemispheres were active during encoding of nameable objects. A similar pattern of lateralized activation was found in the MTL.

The Kelley et al. (1998) study provides important information about the lateralization of memory encoding, but did not examine memory retrieval. A study by Klingberg and Roland (1998) extended this result by examining both encoding and retrieval for pairings of nonverbal patterns and sounds. Subjects learned pattern–sound pairings by trial and error, and brain activity was measured using PET during a period early in training (measuring memory encoding) and a period later in training (measuring memory retrieval). Klingberg and Roland found encoding-specific activation in the right posterior prefrontal cortex (BA 44/6), which was significantly greater than activation in the same region at retrieval. This finding suggests that some regions may exhibit specificity both to the type of materials (verbal or nonverbal) and to the memory processing (encoding or retrieval).

One important question is why these results differ from those of the previous studies, which had led to formulation of the HERA model; particularly of interest is why previous studies of face encoding found left hemisphere prefrontal activation. Differences in tasks may have resulted in selective use of verbal or nonverbal processes during face encoding in these studies, which could have resulted in either left or right hemisphere activation, respectively. Evidence for this account comes from a study by Haxby and colleagues (Haxby et al., 1995), which examined the retention of unfamiliar faces across time. Retention of faces for 1 s resulted in both right and left hemisphere frontal activation, whereas retention of faces for 6 s resulted only in left hemisphere activation. This suggests that the increased amount of encoding time allowed in previous studies may have shifted the subjects' strategy toward verbal labeling of facial features. The findings of Klingberg and Roland (1998) using nonsense patterns suggest that the right hemisphere is the locus of memory encoding when such verbal labeling is discouraged.

The recent results reviewed here represent a significant step in the understanding of the neural architecture of memory encoding because they integrate findings

from lesion and neuroimaging research. Major questions, however, remain to be answered. The HERA model, and the foregoing review, treat memory encoding as if it were a single process mediated by a single frontal lobe region. The actual encoding of a memory, however, undoubtedly involves multiple cognitive processes, including assembling a representation of the stimulus, detecting that the stimulus is novel, relating the stimulus to existing knowledge, and laying down a lasting memory trace of the assembled representation. Indeed, there is already evidence that different regions of the left frontal lobe are specialized for different kinds of verbal encoding processes (Buckner, 1996; Gabrieli et al., 1998). Further, recent findings by Dolan and Fletcher (1997) have suggested separate roles for the left prefrontal cortex and MTL in verbal memory encoding, with the MTL processing stimulus novelty and the prefrontal cortex integrating new stimuli with existing knowledge. Additional studies will continue to characterize the specific contribution of multiple frontal and MTL brain areas to different aspects of memory encoding. Finally, there is still a need to better reconcile lesion and neuroimaging evidence concerning right prefrontal activations for memory retrieval. One approach has been to interpret those activations as short-term memory processes involved in the evaluation of memory judgments, rather than representing long-term memories per se (Wagner et al., 1998).

The most exciting aspect of these recent results is that they begin to demonstrate neural bases for fundamental results from cognitive psychology. One such result is the "picture superiority effect," which refers to the fact that pictures of real objects are remembered far better than words. The results of the Kelley et al. (1998) study offer a simple explanation for this result in neural terms: the involvement of additional right hemisphere brain regions during object encoding that are not active during word encoding results in greater memory for objects. Further research that combines functional brain imaging with lesion studies should continue to provide new insights into the organization of cognitive processes in the brain.

#### Selected Reading

- Buckner, R.L. (1996). *Psychonomic Bull. Rev.* 3, 149–158.
- Buckner, R.L., Corbetta, M., Schatz, J., Raichle, M.E., and Petersen, S.E. (1996). *Proc. Natl. Acad. Sci. USA* 93, 1249–1253.
- Cohen, N.J., and Eichenbaum, H.E. (1993). *Memory, Amnesia, and the Hippocampal System* (Cambridge, MA: MIT Press).
- Dolan, R.J., and Fletcher, P.C. (1997). *Nature* 388, 582–585.
- Gabrieli, J.D.E., Poldrack, R.A., and Desmond, J.E. (1998). *Proc. Natl. Acad. Sci. USA* 95, 906–913.
- Haxby, J.V., Ungerleider, L.G., Horwitz, B., Rapoport, S.I., and Grady, C.L. (1995). *Hum. Brain Mapping* 3, 68–82.
- Kelley, W.M., Miezin, F.M., McDermott, K.B., Buckner, R.L., Raichle, M.E., Cohen, N.J., Ollinger, J.M., Adbudak, E., Conturo, T.E., Snyder, A.Z., and Petersen, S.E. (1998). *Neuron* 20, 927–936.
- Klingberg, T., and Roland, P.E. (1998). *Cereb. Cortex* 8, 73–79.
- Milner, B. (1970). In *Biology of Memory*, K.H. Pribram and D.E. Broadbent, eds. (New York: Academic Press).
- Milner, B. (1982). *Philos. Trans. R. Soc. Lond. B Biol. Sci.* 298, 211–226.
- Nyberg, L., Cabeza, R., and Tulving, E. (1996). *Psychonomic Bull. Rev.* 3, 135–148.
- Poldrack, R.A., and Gabrieli, J.D.E. (1997). *J. Clin. Neurophys.* 14, 294–310.
- Raichle, M.E. (1994). *Annu. Rev. Psychol.* 45, 333–356.
- Scoville, W.B., and Milner, B. (1957). *J. Neurol. Neurosurg. Psychiatry* 20, 11–21.
- Shimamura, A.P. (1995). In *The Cognitive Neurosciences*, M.S. Gazzaniga, ed. (Cambridge, MA: MIT Press).
- Squire, L.R. (1992). *Psychol. Rev.* 99, 195–231.
- Tulving, E., Kapur, S., Craik, F. I.M., Moscovitch, M., and Houle, S. (1994). *Proc. Natl. Acad. Sci. USA* 91, 2016–2020.
- Wagner, A.D., Desmond, J.E., Glover, G.H., and Gabrieli, J.D.E. (1998). *Brain*, in press.